

## A Case of the 10 days

### Case 372

A sixty-seven-year-old male underwent laparotomy for gastric cancer. It revealed advanced cancer with peritoneal dissemination and liver metastasis. Then, after surgical service, he received postoperative chemotherapy. Partial tumor response was obtained (Fig.1).

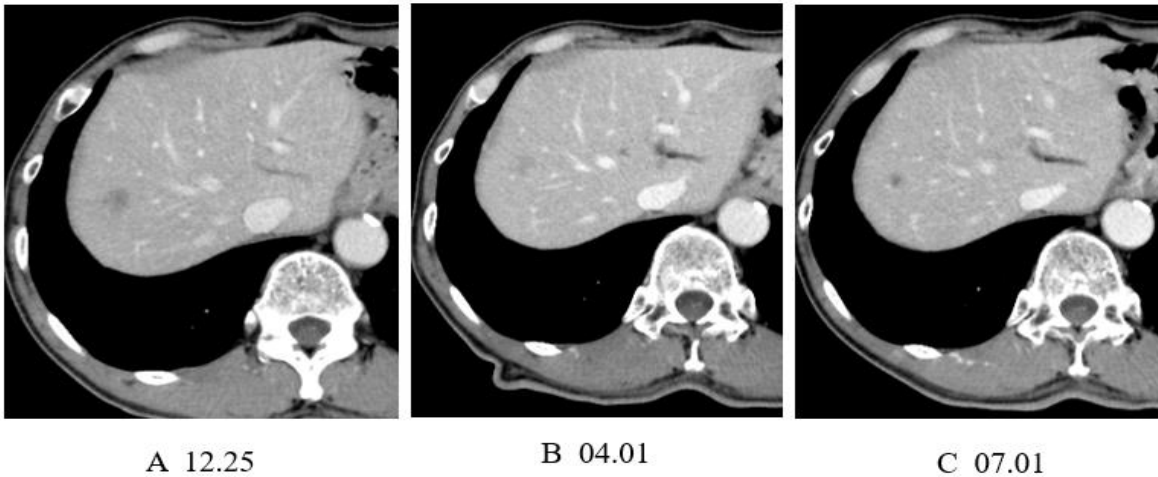


Fig.1 As time went by, a hypo-vascular space occupying lesion at S8 that is suspicious of metastatic tumor from gastric cancer is being shrunk on CT following receiving chemotherapy.

What parameters of laboratory test should be investigated before anti-cancer chemotherapy for patients with advanced gastric cancer?

- A. Human epithelial receptor
- B. Microsatellite
- C. PL-D
- D. CD-28

answer

2025.1.31