

A Case of the 10 days

Case 354

A seventy-year-old female with gastric cancer invaded to transverse colon received chemotherapy and immunotherapy. She took abdomen CT (Figs. 1, 2) for investigation of anti-tumor effect.

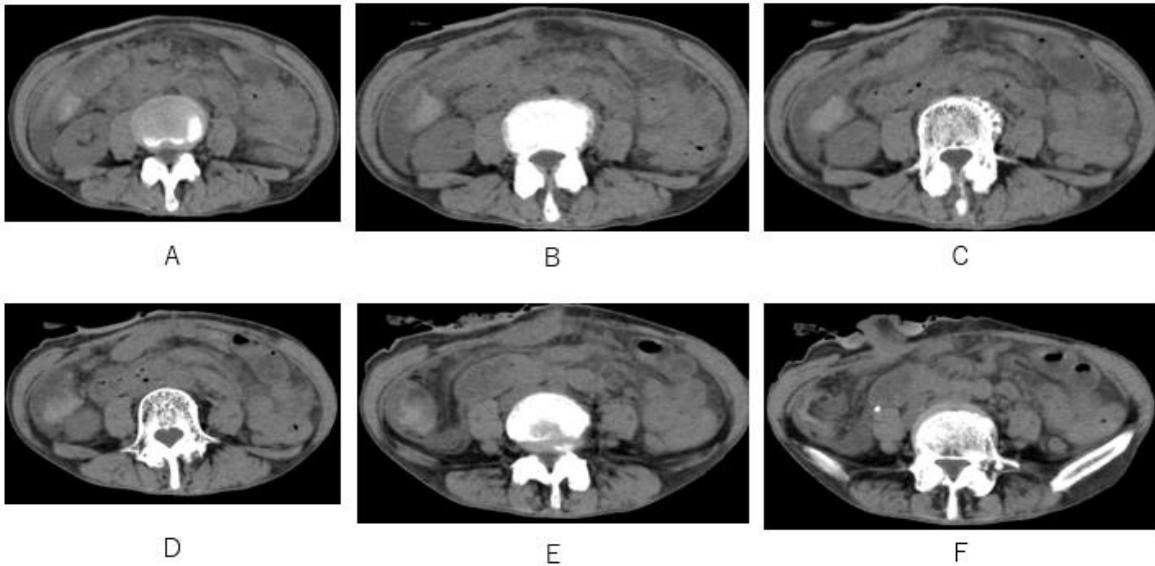


Fig.1 Fluids with high attenuation (CT values; around 60 HU) are depicted on axial CT.

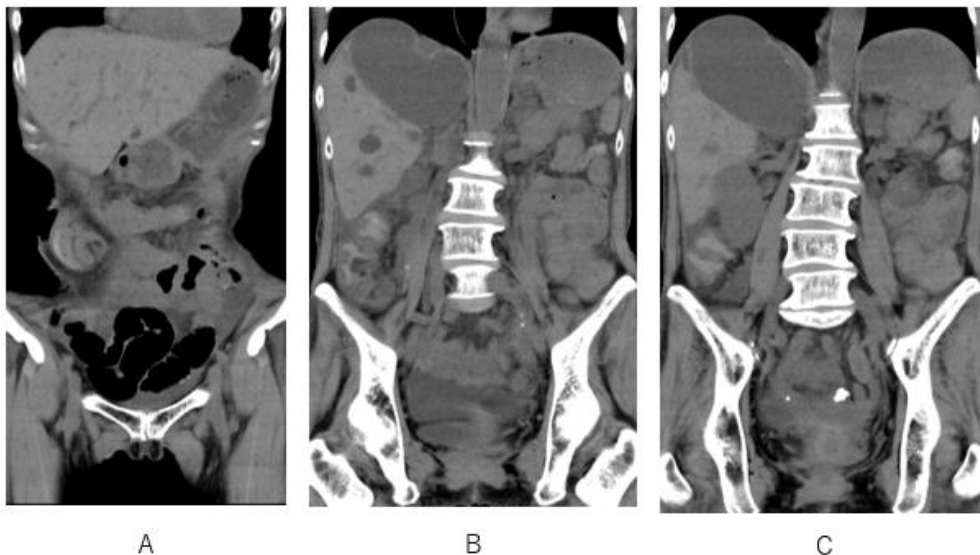


Fig.2 Fluids with high attenuation in cecum and ascending colon are depicted on coronal CT.

What is possible fluids (CT values, around 60 HU) in cecum and ascending colon?

1. Mucin
2. Remnant of contrast medium
3. Hemorrhage
4. All

answer

2024.9.20