

A Case of the 10 days

Case 348

A thirty-two-year-old male presented in our hospital for painful coccyx bone with drain pus and stink, and high fever of 38.9 centigrade degree. He was a farmer often with a chance of sitting down on hard plate. He had a dark body hair. Medical findings revealed self-destruct red-black colored abscess with stink smell at the cranial side of anus. He took pelvic CT for investigation of depth of the lesion (Fig. 1).

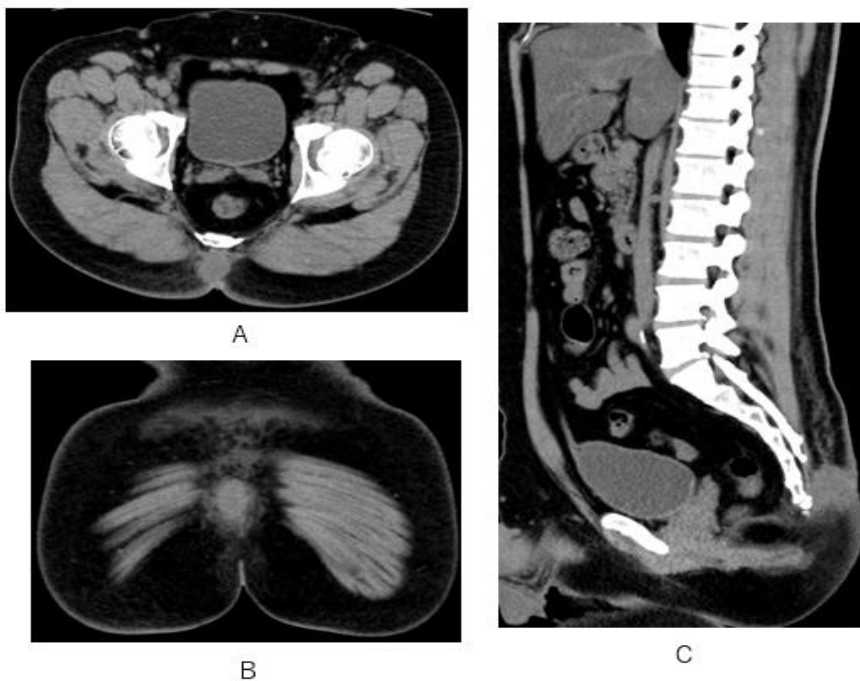


Fig.1 A nodule with soft tissue attenuation is depicted a lesion at subcutaneous midline behind coccyx bone on axial (A), coronal (B) and sagittal (C) CT.

What is clinical diagnosis?

1. Epidermal cyst
2. Paget disease
3. Pilonidal sinus
4. Skin cancer

answer