

A Case of the Week

Case 344

A twenty-nine-year-old male presented in our hospital for high fever of 39.9 degree centigrade, nausea, and throat pain yesterday. Present illness revealed fever of 37.5 degree centigrade. Laboratory test revealed CRP 11.1mg/dL, white blood cells 8560/mm³, neutrophils 92.1%, platelets 119000/mm³, D dimer 41.1microgram/mL.

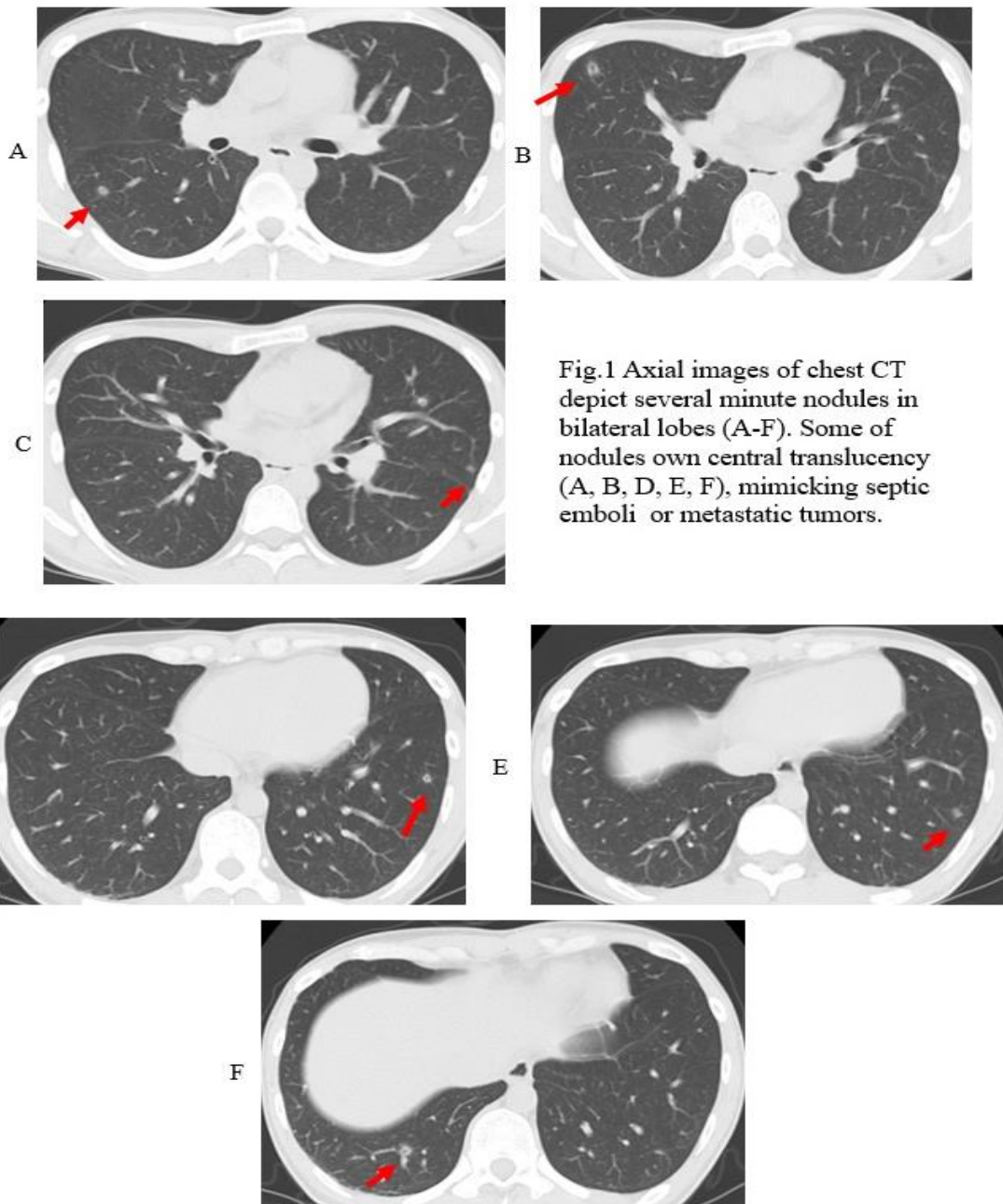


Fig.1 Axial images of chest CT depict several minute nodules in bilateral lobes (A-F). Some of nodules own central translucency (A, B, D, E, F), mimicking septic emboli or metastatic tumors.

What is imaging diagnosis on chest CT?

1. **Septic emboli**
2. **Pulmonary abscess**
3. **Metastatic lung tumors**
4. **Minute meningothelial nodules**
5. **Cryptococcus pneumonia**

answer

2024.7.12