

A Case of 10days

Case 343

A twenty-seven-year-old male was transported to our hospital for high fever of 39 centigrade from care center. He had suffered from complication of encephalitis by rotavirus infection after birth with contracture of upper and lower extremities and with least communication. He was in a state of receiving under continuous positive airway pressure. His body temperature at admission was 40 centigrade. Laboratory test revealed creatinine phosphokinase 335 U/IH, CRP 4.70 mg/dL, white blood cells 9200/mm³.

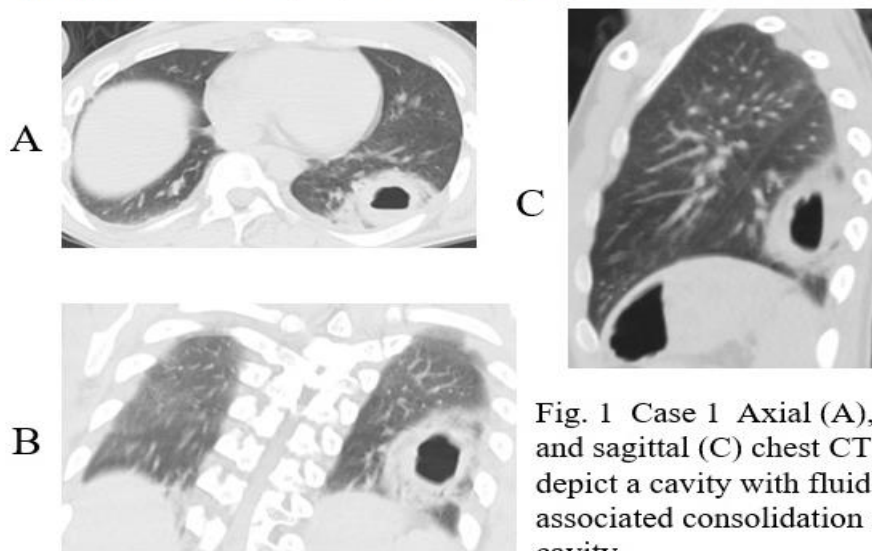


Fig. 1 Case 1 Axial (A), coronal (B), and sagittal (C) chest CT images depict a cavity with fluid level inside associated consolidation surrounding cavity.

What is imaging diagnosis on chest CT in Case 1?

1. Pyothorax
2. Pulmonary abscess
3. Septic emboli
4. Granulomatosis with polyangiitis
5. Pulmonary meningotheliosis

answer

2024.7.5