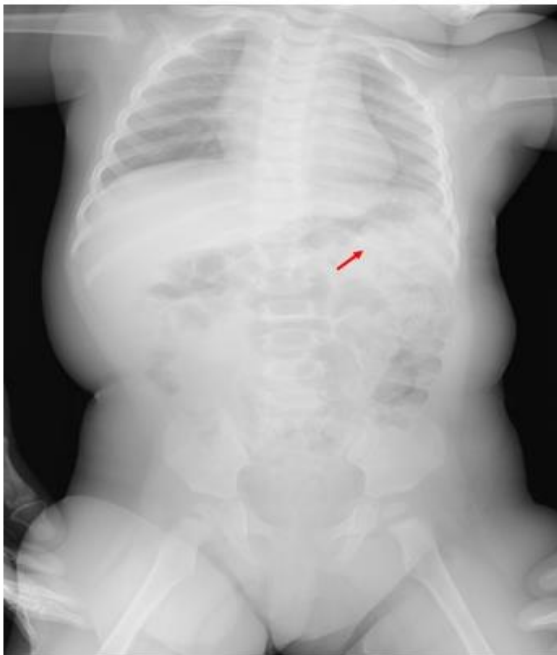


## A Case of 10 days

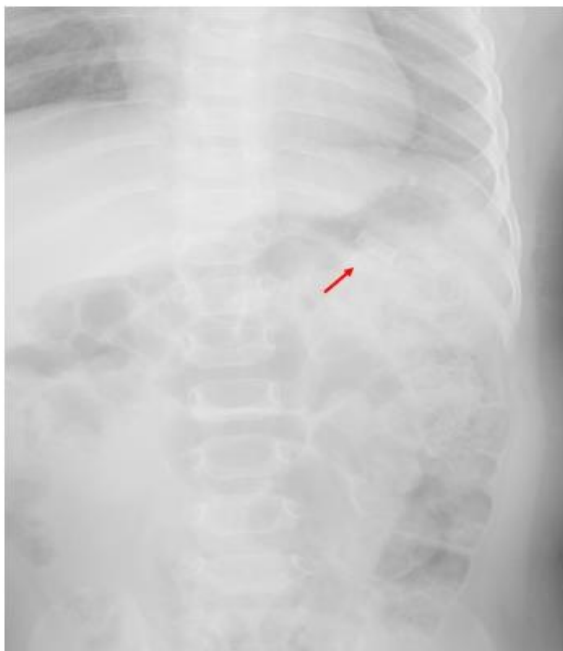### Case 334

An eight-months-old girl infant with her mother presented in our hospital for ingesting cigarettes. When her mother awakened this morning, she realized her child ingested a half of electric cigarettes. Her child vomited and she made her child drink water and thereafter, her child vomited twice. She realized metal piece containing cigarettes was gone. It was unclear whether her child ingested it or not. Soon after, she called came to us. Her infant took a radiograph covering chest and abdomen (Fig A, B).

A



B



Chest and abdomen radiograph depicts a tube-like attenuation (arrow) in left upper abdomen (original size A, magnificant size B).

What is proper management for this case?

---

1. **Activated charcoal**
2. **Atropine**
3. **Intravenous medication**
4. **Ventilation**
5. **Gastric lavage**

answer

2024.5.2